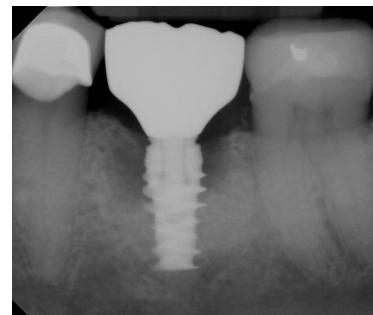


PATIENT HISTORY

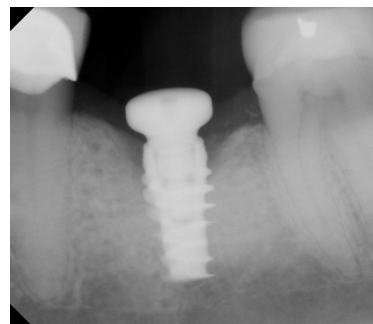
Female patient, age 66, was referred to my office from her general dentist for a recurring infection around screw-retained implant #19 that was not responding to treatment. The implant was placed 6 years prior by a different dentist. During the initial exam on April 19, 2021, the patient indicated the crown had been removed three times and the area cleaned but the inflammation and pus did not resolve. Her overall periodontal health was good, with generalized 2-3mm probing depths. Probing depths around #19 were 6, 9, 5 | 3, 3, 3 with bleeding and suppuration on the buccal. The patient was diagnosed with a stable reduced periodontium with localized peri-implantitis around #19.



Pre-Op
6, 9, 5 | 3, 3, 3

TREATMENT APPROACH

After review of treatment options, the LAPIP protocol was performed on April 27, 2021. The crown was removed by the general dentist prior to the procedure and a narrow healing abutment was placed. A wider healing abutment was placed immediately after LAPIP treatment to compress and maintain the hemostatic blood clot formed as part of the protocol.



9 Month Post-Op
2, 2, 2 | 2, 2, 2

RESULTS

Healing progressed uneventfully with no reports of pain or concerns from the patient. Patient had good oral hygiene and was compliant with every 3-month periodontal maintenance visit. At the initial post operative visits, pus and inflammation was visibly reduced. Radiographs were taken at 9 months with visible bone fill and probing depths reduced to 2mm circumferentially with no recession. Restoration is scheduled to be replaced in a few months.



ABOUT THE AUTHOR: JESSICA ALLEN, DMD, MSD

Dr. Jessica Allen graduated magna cum laude and was inducted into Omicron Kappa Upsilon, a national dental honor society. She received her certificate in Periodontics and Master's of Dental Sciences from Virginia Commonwealth University where she served as chief resident and clinical instructor in the pre-doctoral clinic.

Dr. Allen has also achieved the highest certification in her specialty with board certification in Periodontology and Dental Implant Surgery. She currently holds office as President of Larimer County Dental Society, member of Colorado Dental Association's Council of Component leadership committee, Co-Director for Mountain West Dental Forum, Co-Director of Rocky Mountain Dental Hygiene Study Club and Spear Dental Study Club Specialty Advisor.

Northern Colorado
Periodontics
(970) 680-0364
www.NoCOperio.com
Fort Collins, CO | Greeley, CO

MILLENNIUM
DENTAL TECHNOLOGIES, INC.
(888) 49-LASER www.LANAP.com
21-08-030 REV A